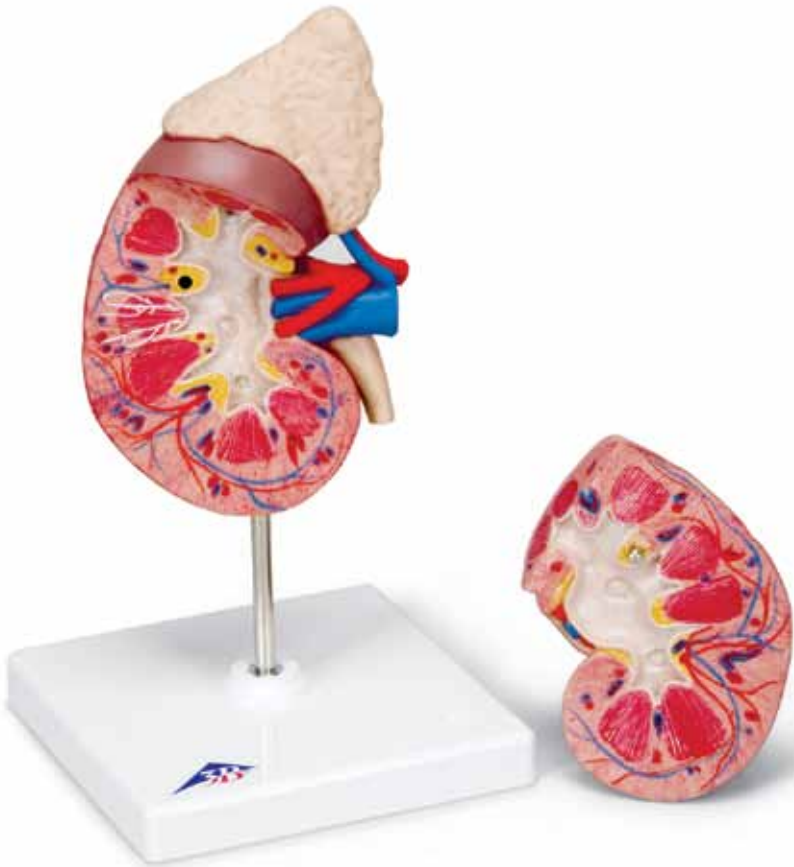



...going one step further



K12
(1000300)

Latin

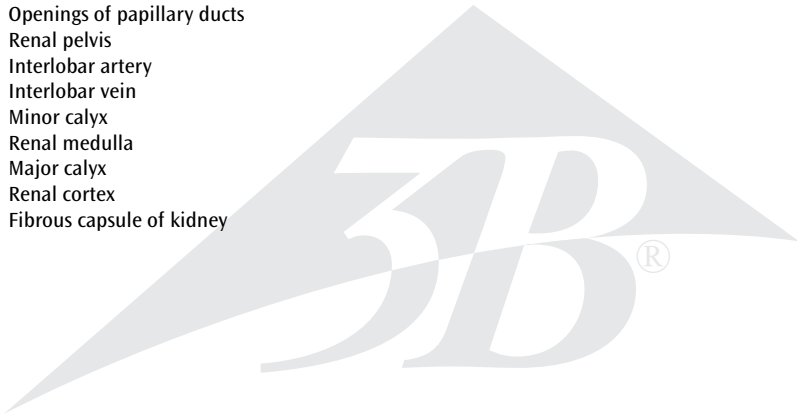
- 1 Glandula suprarenalis
- 2 A. suprarenalis inferior
- 3 V. suprarenalis
- 4 A. renalis
- 5 V. renalis
- 6 Ureter
- 7 V. arcuata
- 8 Pyramides renales
- 9 Basis pyramidis
- 10 A. arcuata
- 11 Columna renalis
- 12 Papilla renalis
- 13 Sinus renalis
- 14 Foramina papillaria [Area cribrosa]
- 15 Pelvis renalis
- 16 A. interlobaris
- 17 V. interlobaris
- 18 Calyx renalis minor
- 19 Medulla renalis
- 20 Calyx renalis major
- 21 Cortex renalis
- 22 Capsula fibrosa renis



Kidney


English

- 1 Suprarenal gland
- 2 Inferior suprarenal artery
- 3 Suprarenal vein
- 4 Renal artery
- 5 Renal vein
- 6 Ureter
- 7 Arcuate vein
- 8 Renal pyramids
- 9 Pyramidal base
- 10 Arcuate artery
- 11 Renal column
- 12 Renal papilla
- 13 Renal sinus
- 14 Openings of papillary ducts
- 15 Renal pelvis
- 16 Interlobar artery
- 17 Interlobar vein
- 18 Minor calyx
- 19 Renal medulla
- 20 Major calyx
- 21 Renal cortex
- 22 Fibrous capsule of kidney



Deutsch


- 1 Nebenniere
- 2 Untere Nebennierenschlagader
- 3 Nebennierenvene
- 4 Nierenschlagader
- 5 Nierenvene
- 6 Harnleiter
- 7 Bogenförmige Vene [Area cribrosa]
- 8 Nierenpyramiden
- 9 Grundfläche der Nierenpyramide
- 10 Bogenförmige Schlagader
- 11 Nierensäule
- 12 Nierenpapille
- 13 Nierensinus
- 14 Harnporen
- 15 Nierenbecken
- 16 In der Nierensäule zwischen den Pyramiden aufsteigende Schlagader
- 17 In der Nierensäule zwischen den Pyramiden aufsteigende Vene
- 18 Kleiner Nierenkelch
- 19 Nierenmark
- 20 Großer Nierenkelch
- 21 Nierenrinde
- 22 Nierenkapsel



Rein

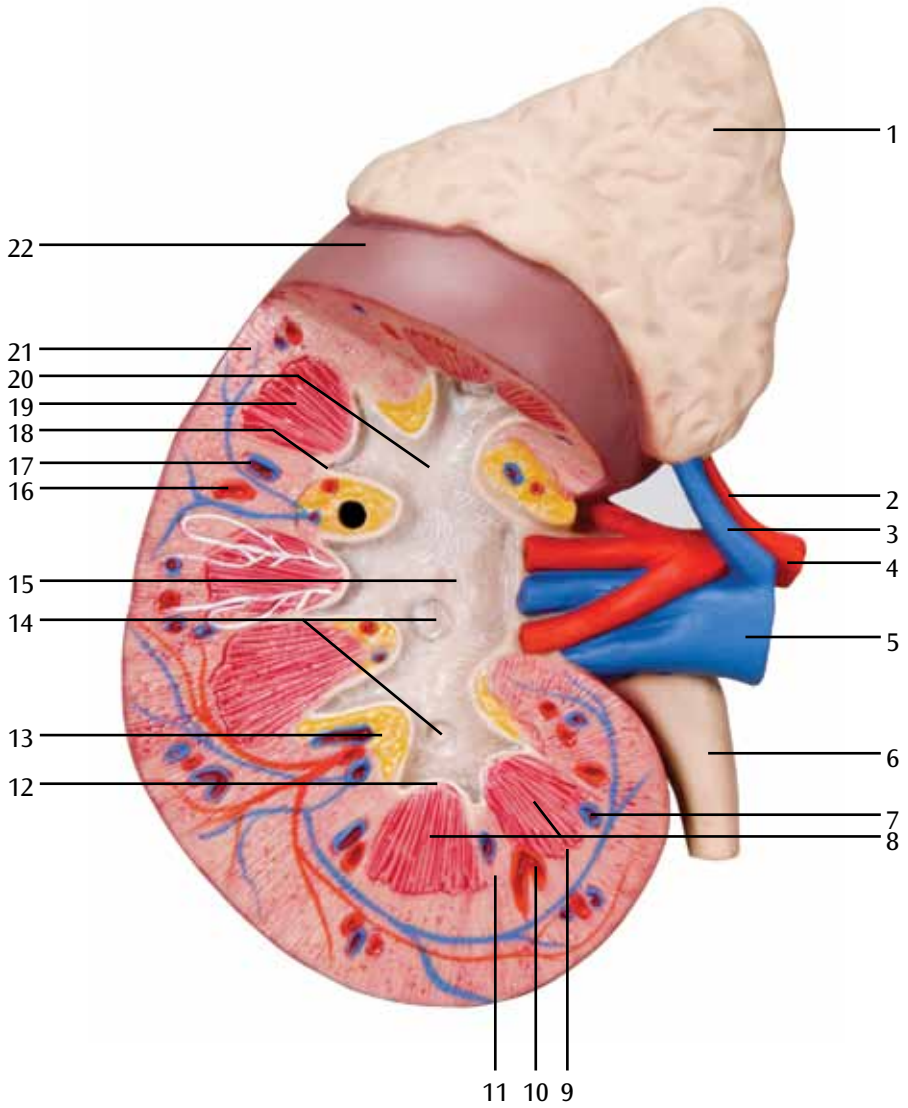
Français

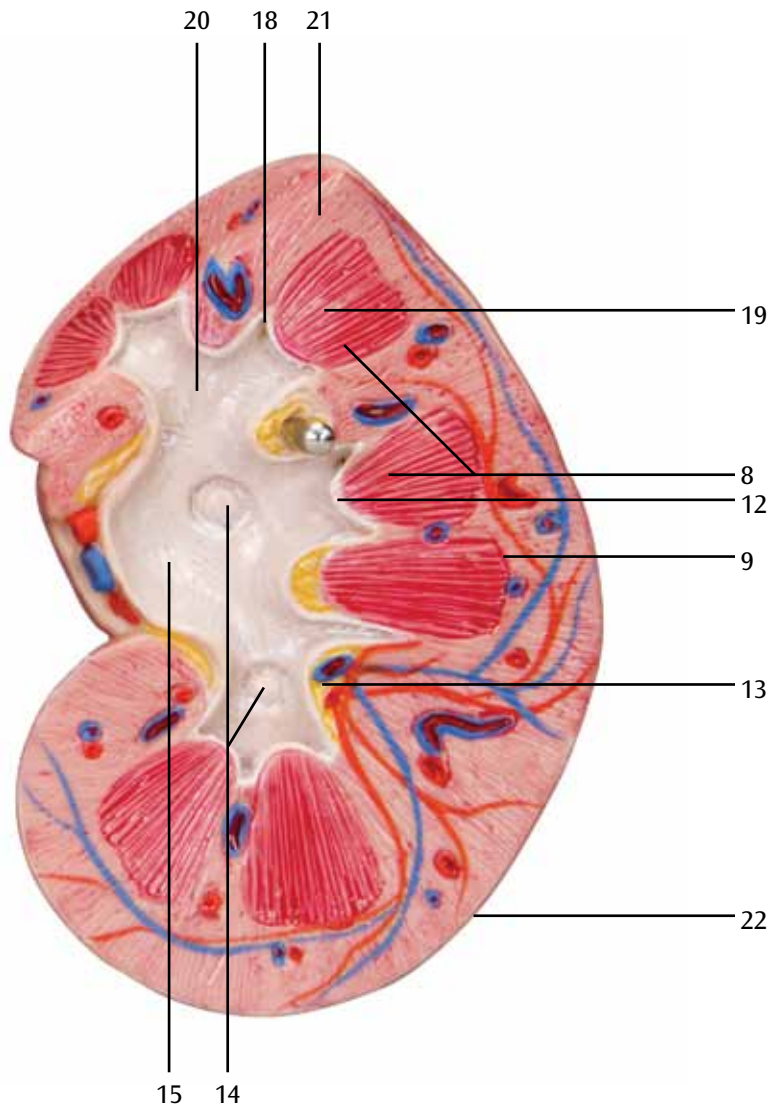
- 1 Glande surrénale
- 2 Artère surrénale inférieure
- 3 Veine surrénale
- 4 Artère rénale
- 5 Veine rénale
- 6 Urètre
- 7 Voûte veineuse sus-pyramidales
- 8 Pyramides rénales
- 9 Base de la pyramide rénale
- 10 Arcades sus-pyramidales
- 11 Colonne rénale
- 12 Papille rénale
- 13 Sinus rénal
- 14 Orifices du canal papillaire
- 15 Rein, pelvis rénal (bassin)
- 16 Artères interlobulaires
- 17 Veine interlobulaire
- 18 Petit calice rénal
- 19 Substance médullaire du rein
- 20 Grand calice rénal
- 21 Rein, cortex
- 22 Capsule du rein



- 1 Glándula suprarrenal
- 2 A. suprarrenal inferior
- 3 V. suprarrenal
- 4 A. renal
- 5 V. renal
- 6 Uréter
- 7 V. arcuata
- 8 Pirámides renales
- 9 Base de la pirámide
- 10 Arteria arqueada
- 11 Columna de Bertin
- 12 Papilas renales
- 13 Seno renal
- 14 Poros urinarios
- 15 Riñón, pelvis
- 16 Aa. interlobares del riñón
- 17 Vena interlobar del riñón
- 18 Cáliz renal menor
- 19 Medula renal
- 20 Cáliz renal mayor
- 21 Riñón, corteza
- 22 Cápsula renal







Rim

Português

- 1 Glândula supra-renal
- 2 Artéria supra-renal inferior
- 3 Veia supra-renal
- 4 Artéria renal
- 5 Veia renal
- 6 Ureter
- 7 Veia arqueada
- 8 Pirâmides renais
- 9 Base da pirâmide renal
- 10 Artéria arqueada
- 11 Coluna renal
- 12 Papilas renais
- 13 Seno renal
- 14 Poros urinários
- 15 Pelve renal
- 16 Artéria interlobar
- 17 Veia interlobar
- 18 Cálice renal menor
- 19 Medula renal
- 20 Cálice renal maior
- 21 Córtex renal
- 22 Cápsula do rim



- 1 Ghiandola surrenale
- 2 A. surrenale inferiore
- 3 V. surrenale
- 4 A. renale
- 5 V. renale
- 6 Uretere
- 7 Vena arcuata
- 8 Piramidi renali
- 9 Base del sistema piramidale
- 10 Arteria arcuata
- 11 Colonna renale
- 12 Papilla renale
- 13 Seni renali
- 14 Pori urinari
- 15 Rene, pelvi
- 16 Arteria interlobare
- 17 Vena interlobare
- 18 Calice renale minore
- 19 Zona midollare
- 20 Calice renale maggiore
- 21 Rene, corteccia
- 22 Perinefrio




腎臓，副腎付き 2 分解モデル

日本語

- 1 副腎
- 2 下副腎動脈
- 3 副腎静脈
- 4 腎動脈
- 5 腎静脈
- 6 尿管
- 7 弓状静脈
- 8 腎錐体
- 9 錐体底
- 10 弓状動脈
- 11 腎柱
- 12 腎乳頭
- 13 腎洞
- 14 乳頭管
- 15 腎盂
- 16 葉間動脈
- 17 葉間静脈
- 18 小腎杯
- 19 腎髓質
- 20 大腎杯
- 21 腎皮質
- 22 腎臓の線維皮膜



- 1 Надпочечник
- 2 Нижняя надпочечниковая артерия
- 3 Надпочечниковая вена
- 4 Почечная артерия
- 5 Почечная вена
- 6 Мочеточник
- 7 Дугообразная вена
- 8 Почечная пирамида
- 9 Основание пирамиды
- 10 Дугообразная артерия
- 11 Почечный столб
- 12 Почечный сосочек
- 13 Почечная пазуха
- 14 Отверстия сосочковых протоков
- 15 Почечная лоханка
- 16 Междолевая артерия
- 17 Междолевая вена
- 18 Малая почечная чашка
- 19 Мозговое вещество почки
- 20 Большая почечная чашка
- 21 Корковое вещество почки
- 22 Фиброзная капсула почки



肾脏与肾上腺模型

中文

- 1 肾上腺
- 2 下肾上腺动脉
- 3 肾上腺静脉
- 4 肾动脉
- 5 肾静脉
- 6 输尿管
- 7 弓形静脉
- 8 肾锥体
- 9 锥体基底
- 10 弓状动脉
- 11 贝坦(氏)肾柱
- 12 肾乳头
- 13 肾窦
- 14 乳头管开口
- 15 肾盂
- 16 叶间动脉
- 17 叶间静脉
- 18 肾小盏
- 19 肾髓质
- 20 肾大盏
- 21 肾皮质
- 22 肾纤维囊



Türkçe

- 1 Böbreküstü bezi
- 2 İnförör böbreküstü arter
- 3 Böbreküstü damar
- 4 Renal Arteri
- 5 Renal Damarı
- 6 Üreter
- 7 Kavisli damar
- 8 Renal Piramitler
- 9 Piramidal taban
- 10 Kavisli arter
- 11 Renal sütun
- 12 Renal papilla
- 13 Renal sinüs
- 14 Papiller yolu açılımı
- 15 Renal pelvis
- 16 Interlobar arter
- 17 Interlobar damar
- 18 Minor kalıs
- 19 Renal medulla
- 20 Majör kalıs
- 21 Renal korteks
- 22 Böbreğin fibröz kapsülü



3B Scientific

A worldwide group of companies



3B Scientific GmbH

Rudorffweg 8 • 21031 Hamburg • Germany

Tel.: + 49-40-73966-0 • Fax: + 49-40-73966-100

www.3bscientific.com • 3b@3bscientific.com

© Copyright 2005 / 2014 for instruction manual and design of product:
3B Scientific GmbH, Germany